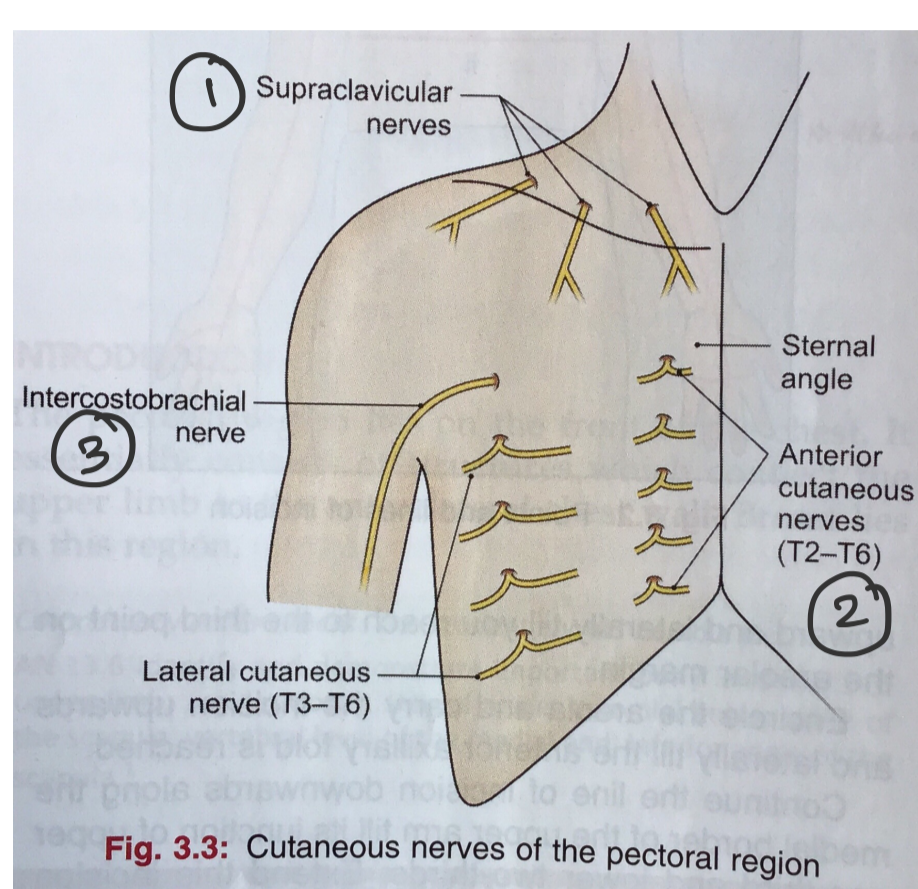


Superficial fascia:-

- The breast is the most important of all contents.
 - ↓
 - in addition to fat,
 - (a) Cutaneous nerves from cervical plexus & intercostal nerves.
 - (b) Cutaneous branches from internal thoracic and posterior intercostal arteries.
 - (c) Platysma.
 - (d) The breast.

Cutaneous Nerves



- ① The medial, intermediate & lateral supraclavicular nerves (are branches of cervical plexus (C₃, C₄)) supply the skin over the upper half of deltoid and from the clavicle to 2nd rib.
- ② The anterior & lateral cutaneous branches of the 2nd to 6th (T₂-T₆) intercostal nerve supply the skin below 2nd rib.
- ③ The intercostobrachial nerve of T₂ supplies the skin of the floor of axilla and upper half of medial side of arm.

Cutaneous Vessels :

- Very small
- The anterior cutaneous nerves are accompanied by the perforating branches of internal thoracic artery.
- 2nd, 3rd & 4th of these branches are large in females for supplying the breast.
- The lateral cutaneous nerves ↓ accompanied by lateral cutaneous branches of posterior intercostal arteries.

Platysma

- Thin, broad sheet of sub-cutaneous muscle.
- arise from deep fascia covering pectoralis major; run upward and medially, crossing clavicle and side of the neck; inserted into base of mandible and into skin over the posterior and lower part of face.
- supplied by facial nerve.
- protects external jugular vein from external pressure.